

Foot drop - an uncommon presentation of FOLFOX toxicity

Tânia Madureira¹, Joana Magalhães¹, Pedro Bento Vilas², Beatriz Gosálbez¹, Irene Furtado¹

RESUMO

Aquimioterapia com FOLFOX (oxaliplatina, leucovorina e 5-fluorouracilo) é frequentemente utilizada em doentes com cancro colorretal. Os sais de platina são conhecidos por serem uma classe de quimioterápicos que comumente induzem neurotoxicidade periférica. Na toxicidade induzida pela oxaliplatina, os sintomas sensitivos são os mais frequentes. Neste artigo, apresentamos dois casos clínicos de pacientes com adenocarcinoma de cólon, ambos submetidos à quimioterapia com FOLFOX4, e que desenvolveram neurotoxicidade incomum, apresentando pé pendente após o terceiro ciclo de tratamento. Esta manifestação clínica pode ser explicada por dano axonal nos neurônios motores periféricos do nervo peroneal comum (fibular), que fornece inervação motora aos músculos do pé. A paralisia do nervo fibular causa fraqueza súbita nos músculos do pé, que parece ser temporária. Ambos os doentes recuperaram completamente do evento sem necessidade de ajustes no tratamento, nem introdução de medicamentos diferentes. A apresentação de pé pendente como toxicidade da quimioterapia ainda é pouco compreendida. Os casos relatados mostram o pé pendente como uma manifestação grave e incomum de neuropatia induzida por FOLFOX, que pode ser transitória, e não requer necessariamente intervenção específica.

Palavras-chave: Pé Pendente; Oxaliplatina; Neurotoxicidade.

ABSTRACT

Chemotherapy based on FOLFOX (oxaliplatin, leucovorin, and 5-fluorouracil) regimen is frequently used in colorectal cancer patients. Oxaliplatin and other platinum agents are known to be a class of chemotherapy drugs that commonly induce peripheral neurotoxicity. The most frequent oxaliplatin related neurotoxicity is sensitive symptoms. Here, we present two cases of patients with colon adenocarcinoma, both undergoing chemotherapy with FOLFOX4, who developed uncommon neurotoxicity, presenting with foot drop after the third treatment cycle. Foot drop may be explained by axonal damage of peripheral motor neurons of the common peroneal (fibular) nerve, which provides motor innervation to the foot muscles. Peroneal nerve palsy causes sudden weakness in the muscles of the foot that seems to be temporary. Both patients completely recovered from the event. There was no need for treatment adjustments, neither introduction of different drugs. Foot drop as chemotherapy toxicity is still poorly understood. The reported cases show foot drop as a severe and uncommon manifestation of FOLFOX-induced neuropathy, that might be transitory, and does not necessarily requires specific intervention.

Keywords: Foot Drop; Oxaliplatin; Neurotoxicity.

¹ University Hospital Center of Algarve, Medical Oncology Department, Faro, Portugal.

² University Hospital Center of Algarve, Internal Medicine Department, Faro, Portugal.

Associate Editor Responsible:

Angélica Nogueira Rodrigues
Faculdade de Medicina da
Universidade Federal de Minas Gerais
Belo Horizonte/MG, Brazil

Corresponding author:

Tânia Sofia Mendonça Madureira
E-mail: taniaofiamm@hotmail.com

Conflict of Interests:

None.

Received on: 02 February 2022

Approved on: 04 May 2022

Publication Date: 18 August 2022

DOI: 10.5935/2238-3182.2022e32406

INTRODUCTION

The FOLFOX regimen (based on oxaliplatin, leucovorin, and 5-fluorouracil) is frequently used as treatment of colorectal cancer¹. Oxaliplatin and other platinum agents are a drug class in which peripheral neuropathy is a common adverse effect². Many patients have neurological toxicity during and after treatment with these protocols. The most frequent oxaliplatin related neurotoxicity is sensitive symptoms². Peripheral motor neuropathy and autonomic symptoms are less common. The severity of neurological adverse effects varies from mild paresthesia to severe pain with limitation in quality of life³. This often leads to changes in chemotherapy protocols such as dose reduction, delay or treatment suspension³.

In this study, we report uncommon form of oxaliplatin-related neurotoxicity, in two cases of colon cancer patients, during their chemotherapy with FOLFOX4 regimen.

CASE REPORT

CASE 1

A 59 years old female presented with constipation, abdominal pain and asthenia, performance status 1 and a positive fecal occult blood test. The colonoscopy was performed, showing a stenosing tumor at 50cm from anal margin, which pathological report was compatible with differentiated colon adenocarcinoma. Promptly, the patient underwent left hemicolectomy. The final pathological staging was pT3dpN1 cM1 (liver), RAS wildtype. Palliative chemotherapy with FOLFOX and panitumumab was initiated. She complained about transient CTCAE grade 1-2 paresthesia and sensibility changes in the oral cavity. After 3 cycles, the patient sought medical care due to frequent stumbles and falls, few days of its onset. She presented with a right sided foot drop, with a motor strength grade 3 in the scale ranging 0 to 5. The remaining physical exam was unremarkable. She denied traumatic injury. Radicular compression was the main suspicion. Further investigation was performed. Blood tests and Brain CT scan (Figure 1) were normal. MRI revealed bone metastasis in lumbar and sacral spine without pathologic fractures, medullar or radicular compression (Figure 2). A neurosurgeon and a rehabilitation doctor excluded spine or central causes. The patient got spontaneously better after one month. Treatment with FOLFOX was never changed or suspended and foot drop did not recur.

CASE 2

A 54 years old man presented with weight loss, performance status 0 and abnormal finding on screening colonoscopy. Biopsy revealed the diagnosis of well-differentiated colon adenocarcinoma and patient had sigmoidectomy surgery. Final pathological stage was pT3b N2a cM0, RAS wild type. FOLFOX adjuvant chemotherapy was proposed. After 3 cycles, the patient reported paresthesia

in both hands and a left sided foot drop, with no traumatic history. The patient was admitted at the emergency room, where a full neurologic evaluation was performed by the neurologist, who confirmed the peripheral and focal weakness of the left foot with any other abnormalities. Blood tests were normal. He was discharged with recommendation of physiotherapy program of rehabilitation. All the clinical manifestations disappeared spontaneously two weeks later. Treatment with FOLFOX was never changed or suspended during this time.

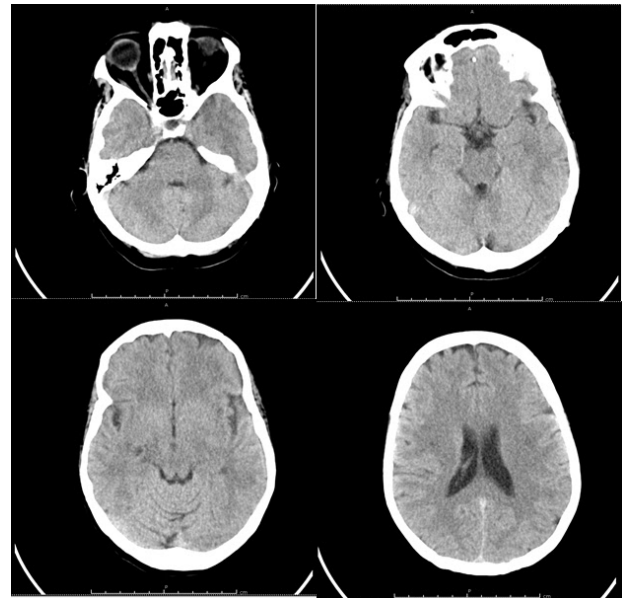


Figure 1. Brain CT scan images without abnormalities (case 1).

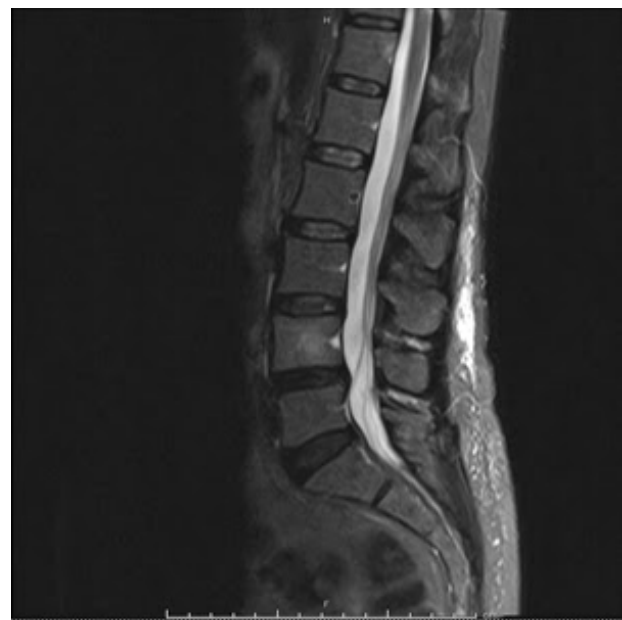

Figure 2. MRI of lumbar and sacral spine without pathologic fractures or spinal cord compression.

DISCUSSION

Usually, chemotherapy neurotoxicity is dose dependent and cumulative². Oxaliplatin is frequently associated with peripheral neurotoxicity, specially as with paresthesia/dysesthesia of the extremities and perioral region³. However, this drug may also be related to neuropathy by a non-dose dependent process. As described in MOSAIC trial, 92% of patients treated with a FOLFOX scheme experienced neuropathy of any degree during treatment, and in up to 30% of these patients, the symptoms remained even after the conclusion of the treatment^{1,4}.

Our patients developed foot drop after the third treatment cycle (total cumulative dose of oxaliplatin of 255mg/m² - 85mg/m²/cycle). We assume that chemotherapy was responsible for this manifestation and interpreted as peripheral motor neuropathy caused by oxaliplatin toxicity. Foot drop can be caused also by central nervous system pathology, stroke or tumor, spine lesion or mononeuropathy/vasculitis. Extensive evaluation and complementary exams were performed to rule out these differential diagnosis.

There is still a lot to know about the mechanism of how chemotherapy agents provoke neuropathy. In the literature, it is hypothesized that platinum drugs target the dorsal root ganglion, with platinum DNA-binding resulting in neuropathy. Both of our patients were in treatment with oxaliplatin and had associated neuropathy. The mechanism of pathogenesis was not clarified.

Foot drop can be explained by axonal damage of peripheral motor neurons of the common peroneal (fibular) nerve that provides motor innervation to the foot muscles. Peroneal nerve palsy causes sudden weakness in the muscles of the foot that seems to be temporary. Both patients completely recovered from the event and there was no need for treatment adjustments, neither addition of different drugs.

The incidence of peroneal nerve palsy related with chemotherapy is unknown⁵.

Among the recommended treatment, it is included dose decreasing, interruption and discontinuation of chemotherapy agent. Physiotherapy might be helpful to stabilize the ankle and maintaining the range of movements⁵. Duloxetine is recommended as pharmacological approach, but strong evidences of its benefit is still lacking⁵.

In both cases reported in this paper, the recovery was prompt and spontaneous, and no dose modification were necessary. It differs from other publications, such as Dharmapuri and Pintova (2019)⁵, in which the patients took longer to recover and required physical therapy.

CONCLUSION

The foot drop as a chemotherapy toxicity entity is still poorly understood. Physicians of different specialties should be aware that oxaliplatin neurotoxicity pattern includes this type of manifestations. Further studies are needed to better describe this clinical finding in order to prevent it and to avoid potentials delays/suspensions in chemotherapy treatments.

CONFLICTS OF INTEREST

The authors do not have any conflicts of interest to declare.

COPYRIGHT

Copyright© 2020 Madureira et al. This is an Open Access article distributed under the terms of the Creative Commons Attribution License, which permits unrestricted use, distribution, and reproduction in any medium, provided the original article is properly cited.

REFERENCES

1. André T, Gramont A, Vernerey D, Chibaudel B, Bonnetain F, Tijeras-Raballand A, et al. Adjuvant fluorouracil, leucovorin, and oxaliplatin in stage II to III colon cancer: updated 10-year survival and outcomes according to BRAF mutation and mismatch repair status of the MOSAIC study. *J Clin Oncol*. 2015 Dec;33(35):4176-87. DOI: <https://doi.org/10.1200/JCO.2015.63.4238>
2. Argyriou AA. Updates on oxaliplatin-induced peripheral neurotoxicity (OXAI PN). *Toxics*. 2015 May;3(2):187-97. DOI: <https://doi.org/10.3390/toxics3020187>
3. Banach M, Zygulska AL, Krzemieniecki K. Oxaliplatin treatment and peripheral nerve damage in cancer patients: a Polish cohort study. *J Cancer Res Ther*. 2018 Jul/Sep;14(5):1010-3. DOI: https://doi.org/10.4103/jcrt.JCRT_971_16
4. André T, Boni C, Mounedji-Boudiaf L, Navarro M, Tabernero J, Hickish T, et al. Oxaliplatin, fluorouracil, and leucovorin as adjuvant treatment for colon cancer. *N Engl J Med*. 2004 Jun;350(23):2343-51. DOI: <https://doi.org/10.1056/NEJMoa032709>
5. Dharmapuri S, Pintova S. Platinum and taxane induced common peroneal nerve palsy (foot drop): case series and review of the literature. *Ann Oncol*. 2019 Jul;4:1611.

